

# Synchronous Oral Squamous Cell Carcinoma in A Female: A Rare Case Report

Dr. Sachin S Kadam<sup>1</sup>, Dr. Tejaswini Kadam<sup>2</sup>

<sup>1</sup>Dept of Surgical Oncology, Currae Cancer & Multispeciality Hospital, Mumbai, India

<sup>2</sup>Dept of Ophthalmology, Shree Ramakrishna Netralaya Super Speciality Eye Hospital, Mumbai, India

**\*Corresponding Author:** Dr. Sachin S Kadam. Dept of Surgical Oncology, Currae Cancer & Multispeciality Hospital, Mumbai, India.

**Received:** 24 February 2023; **Accepted:** 12 April 2023; **Published:** 14 April 2023.

**Citation:** Dr. Sachin S Kadam (2023). Synchronous Oral Squamous Cell Carcinoma in A Female: A Rare Case Report. Journal of Clinical Oncology Reports.2(3). DOI:10.58489/2836-5062/012.

**Copyright:** © 2023 Dr. Sachin S Kadam; this is an open-access article distributed under the Creative Commons Attribution License, which permits unrestricted use, distribution, and reproduction in any medium, provided the original work is properly cited.

## Abstract

Worldwide, the number of new cases of lip and oral cavity cancer in both sexes, all age groups in 2020 are around 377713 and the number of deaths in both sexes, all age groups are around 177757. In India, lip and oral cavity cancer ranks at 2nd position with incidence around 10.3%, mortality 8.8% and 5- year prevalence around 21.77%. Multiple theories have been put forth describing the multifocal origin of squamous cell carcinoma (SCC) of the oral and aerodigestive tract. "Field Cancerization" is the first theory described in oral squamous cell carcinoma (SCC) which explains the multifocal or synchronous origin of the SCC. Synchronous carcinomas are defined as second neoplasms at the same time or within 6 months period of primary lesions. After that, they are described as metachronous neoplasms. The criteria to describe synchronous tumors were elaborated by Warren and Gates and Moertel et al. "Field Cancerization" theory was explained by widespread epithelial exposure to carcinogens; however, the alternative theory of common clonal origin is now supported by the recent molecular studies. Second Primary Tumors (Synchronous or Metachronous) are usually more aggressive, more resistant, metastasizes early and they require a more aggressive treatment strategy. Hence, their early detection is the crucial step in planning the best possible management. We are reporting an unusual case of synchronous oral squamous cell carcinoma in 58-year-old female who underwent surgery followed by adjuvant treatment after diagnosis.

**Keywords:** Synchronous, Oral Squamous, Cell Carcinoma, more aggressive, more resistant

## Introduction

Worldwide, the number of new cases of lip and oral cavity cancer in both sexes, all age groups in 2020 are around 377713 and the number of deaths in both sexes, all age groups are around 177757 [ 1]. In India, lip and oral cavity cancer ranks at 2nd position with incidence around 10.3%, mortality 8.8% and 5- year prevalence around 21.77% [ 2]. Multiple theories have been put forth describing the multifocal origin of squamous cell carcinoma (SCC) of the oral and aerodigestive tract [ 3]. "Field Cancerization" is the first theory described in oral squamous cell carcinoma (SCC) which explains the multifocal or synchronous origin of the SCC [ 4]. Synchronous carcinomas are defined as second neoplasms at the same time or within 6 months period of primary lesions. After that, they are described as metachronous neoplasms. [ 5].

The criteria to describe synchronous tumors were elaborated by Warren and Gates and Moertel et al [ 6]. "Field Cancerization" theory was explained by widespread epithelial exposure to carcinogens; however, the alternative theory of common clonal origin is now supported by the recent molecular studies [ 7]. Second Primary Tumors (Synchronous or Metachronous) are usually more aggressive, more resistant, metastasizes early and they require a more aggressive treatment strategy. Hence, their early detection is the crucial step in planning the best possible management [ 8]. We are reporting an unusual case of synchronous oral squamous cell carcinoma in 58-year-old female who underwent surgery followed by adjuvant treatment after diagnosis.

### Case report

A 58-year-old lady with Eastern Co-operative Oncology Group Performance Status 1 (ECOG PS-1) presented to our clinic. She had history of ulcerative lesion at right lower alveolus for the last 2 months. She was receiving treatment for diabetes mellitus and hypertension. There was no contributory family, past and surgical history. She had history of tobacco chewing for the last 25 years in the form of 'Pan'. On clinical examination, there were two lesions in the oral cavity. One lesion was located at right lower gingivo-buccal sulcus of size 2.5x 1cm in relation to canine tooth and second lesion was located at right retromolar triangle with size 1.5 x 1cm. Right level IB lymph node was enlarged. Punch biopsy was already taken by the treating physician and it was reported as moderately differentiated squamous cell carcinoma. Rest of the systemic examination was unremarkable. She had been advised CECT of oral cavity, neck and chest. CECT was suggestive of same findings with no distant metastasis. Case was discussed in our institutional multidisciplinary tumor board and board's decision was to go ahead with composite resection with neck dissection and reconstruction. After getting fitness from anesthesiologist, she underwent composite resection with right extended hemimandibulectomy with right Modified radical neck dissection (Type III) with reconstruction by pectoralis major myocutaneous flap with tracheostomy. Microvascular free fibula flap was advised to the patient and her relatives, however, they opted for pedicled flap. Her postoperative course was uneventful and she was discharged on 7th postoperative day. Tracheostomy was decannulated on 12th postoperative day. Final histopathology report was suggestive of 8th edition AJCC staging as pT2 pN3b pM0 (Tumor size (Both) was < 2cm)

### Discussion

Synchronous SCC are also described as second primary tumors. They grow at the same time with primary SCC or within 6-month period of primary SCC. Warren and Gates and Moertel described the criteria of synchronous tumor as follows (1) all the tumors had to be histologically malignant (2) all had to be distinct masses separated by normal tissue at least by 2 cm (if the intervening mucosa demonstrates dysplasia, it is considered as multicentric primary) (3) the possibility that the tumors could be metastatic had to be excluded histologically. Slaughter et al. [4] had proposed the theory of "field cancerization" whereby multiple tumors could originate independently in an area of epithelium pre-conditioned to cancer development by long-term exposure to carcinogens. The alternate theory is that multiple tumors in the

head and neck are of common clonal origin, and has gained support as a result of the detection of identical genetic alteration in these tumors [9].

A study by Dissanayaka WL et al [6], reported 100% male predominance of synchronous SCCs, with no synchronous occurrence in female patients. Contradictory to it, our index case is a female. The most common site of occurrence of synchronous SCCs is tongue (33.3%) followed by buccal mucosa (26.7%) [3]. Our index case had lesions involving right lower alveolus which is considered to be a rare site [7]. The reported age for synchronous SCC is more than 40 years which matches with our index case's age i.e., 58 years. Tobacco and alcohol are considered as the most carcinogenic agents involved in field cancerization of the epithelium which leads to pronounced genetic changes, ultimately resulting in synchronous and metachronous cancers. Synchronous SCCs are more likely to occur if the index tumor is located in the lower part of the oral cavity (floor of mouth, lower alveolus, retromolar triangle) than if the tumor is located in the upper part of the oral cavity (buccal mucosa, tongue or palate). Our Index case had primary tumor located in lower alveolus. As per the reported case series, onset of synchronous SCC decreases the 5-year survival by 18-30% as compared to those with only a single primary tumor [3].

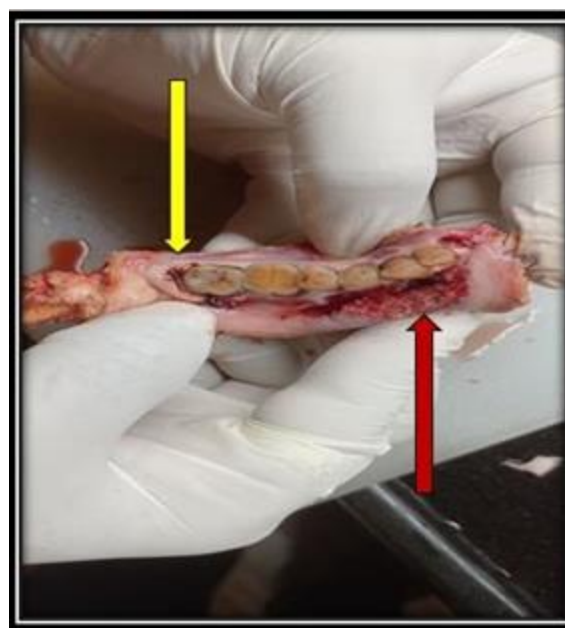
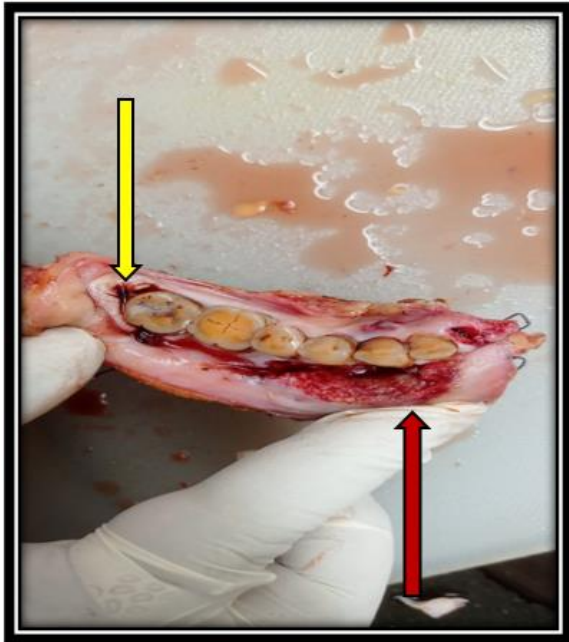


Fig 1: Retromolar Trigone lesion (Yellow Arrow)

Over the last decade, there is an increasing trend of cases of multiple primary oral SCC. These cases need special attention as synchronous or metachronous cancers decreases the overall survival rate. A complete clinical examination of the oral cavity, oropharynx and larynx is necessary to avoid missing of second cancer. As the disease is



**Fig 2:** Gingivo-Buccal Sulcus Lesion (Red Arrow)

aggressive, the treatment plan should be aggressive. Most of the cases of synchronous cancer requires adjuvant treatment. A periodic follow up protocol should be planned for these patients as chances of recurrences are more. Our index case had completed adjuvant treatment and she is in periodic follow up with us. She had been explained the nature of synchronous SCC. Thus, this is a rare case of synchronous oral squamous cell carcinoma involving lower alveolus in a female patient.

When a metachronous SCC develops after the complete treatment of primary SCC, a multidisciplinary treatment approach is necessary to address the tumour with aggressiveness as this cancer will be more resistant and aggressive. Hence a long-term surveillance is mandatory to detect the local recurrence of the primary tumour and to monitor the therapy and its complications. Metachronous or synchronous SCC diagnosis is purely histopathological. Thus, biopsy of the second primary tumour is mandatory for final confirmation.

### Conclusion

Synchronous squamous cell carcinomas of the oral cavity are considered an aggressive and resistant variety. They metastasize earlier as compared to primary and requires an aggressive treatment strategy. Lower alveolus synchronous cancer in females is an extremely rare scenario.

### References

1. <https://gco.iarc.fr/today/data/factsheets/cancers/1-Lip-oral-cavity-fact-sheet.pdf> (Source – GLOBOCAN 2020) 2.
2. <https://gco.iarc.fr/today/data/factsheets/populations/356-india-fact-sheets.pdf> (Source –

GLOBOCAN 2020) 3.

3. Cianfriglia, F., Di Gregorio, D. A., & Manieri, A. (1999). Multiple primary tumours in patients with oral squamous cell carcinoma. *Oral oncology*, 35(2), 157–163.
4. SLAUGHTER, D. P., SOUTHWICK, H. W., & SMEJKAL, W. (1953). Field cancerization in oral stratified squamous epithelium; clinical implications of multicentric origin. *Cancer*, 6(5), 963–968.
5. Dissanayaka, W. L., Jayasooriya, P. R., Kumarasiri, P. V., & Tilakaratne, W. M. (2010). A histopathologic comparison between synchronous and single primary oral squamous cell carcinomas. *Oral surgery, oral medicine, oral pathology, oral radiology, and endodontics*, 109(5), 732–738.
6. Munde, A., Karle, R., & Wankhede, P. (2014). Synchronous multiple oral squamous cell carcinomas: Report of a case. *SRM Journal of Research in Dental Sciences*, 5(3), 207.
7. Bedi, G. C., Westra, W. H., Gabrielson, E., Koch, W., & Sidransky, D. (1996). Multiple head and neck tumors: evidence for a common clonal origin. *Cancer research*, 56(11), 2484-2487.